Journal of Plastic, Reconstructive & Aesthetic Surgery (2009) **62**, 1464—1469

JPRAS
An International Journal of Surgical Reconstruction
www.JPRASurg.com

Preoperative planning for DIEP breast reconstruction: early experience of the use of computerised tomography angiography with VoNavix 3D software for perforator navigation

M.D. Pacifico [a,*], M.S. See [a], N. Cavale [a], J. Collyer [b], I. Francis [c], M.E. Jones [a], A. Hazari [a], J.G. Boorman [a], R.W. Smith [a]

[a] *Department of Plastic Surgery, Queen Victoria Hospital, Holtye Road, East Grinstead, West Sussex RH19 3DZ, UK*
[b] *Department of Oral and Maxillofacial Surgery, Queen Victoria Hospital, Holtye Road, East Grinstead, West Sussex RH19 3DZ, UK*
[c] *Department of Radiology, Queen Victoria Hospital, Holtye Road, East Grinstead, West Sussex RH19 3DZ, UK*

Received 19 December 2007; accepted 19 April 2008

KEYWORDS
DIEP;
CTA;
3D analysis;
Perforator;
Breast reconstruction;
TRAM

Summary The deep inferior epigastric perforator (DIEP) flap is normally the first choice in breast reconstruction; however, due to the considerable vascular anatomical variation and the learning curve for the procedure, muscle-sparing transverse rectus abdominis musculocutaneous (TRAM) flaps are still frequently performed to reduce the rate of complications. Accurate preoperative investigation of the perforators would allow better operative preparation and possibly shorten the learning curve.

In an effort to increase accuracy of preoperative planning and to aid preoperative decision-making in free abdominal flap breast reconstruction, we have acquired the use of VoNavix, software that creates three dimensional images from computerised tomography angiography (CTA) data. The use of the VoNavix software for analysis of CTA provides superior imaging that can be viewed in theatre. It, together with CTA, enables decisions to be made preoperatively, including: which side to raise the flap; whether to aim for a medial or lateral row perforator; whether to take a segment of muscle and whether to expect an easy or difficult dissection.

We have now performed over 60 free abdominal flap breast reconstructions aided with CTA, and 10 of these cases also used VoNavix technology. This paper presents our initial experience with the use of this software, illustrated with three patient examples. The advantages and disadvantages are discussed.

* Corresponding author. Tel.: +44 01342 414000; fax: +44 01342 414121.
E-mail address: marcpacifico@dial.pipex.com (M.D. Pacifico).

1748-6815/$ - see front matter
doi:10.1016/j.bjps.2008.04.056

The deep inferior epigastric perforator (DIEP) flap is currently the first choice in autologous breast reconstruction.[1] Surgical techniques are continuously being refined, in order to improve patient safety, reduce operative time and improve flap reliability. Due to the significant variation in vascular anatomy of the abdominal wall,[2] precise preoperative mapping of the perforating vessels would be invaluable in the planning for flap reconstruction. Furthermore, it would reduce intraoperative decision-making (such as deciding which perforator to use) potentially contributing to a significant reduction in operative time. For example, if there is a long intra-muscular course, in our unit, we would choose to perform a muscle-sparing transverse rectus abdominis musculocutaneous (TRAM) flap (MS-2), rather than a DIEP flap. This is because the extensive muscular dissection required in this situation offsets any advantages of a DIEP flap. It follows that accurate preoperative decision-making on the most appropriate abdominal flap for a particular patient should result in faster operative times, improve patient safety and flap reliability.

We have recently acquired the use of VoNavix software [IVS solutions, Germany] that can be used in conjunction with computerised tomography angiography (CTA). This non-invasive tool has been shown in other surgical fields to precisely delineate the vasculature in various body regions and can provide a detailed three-dimensional (3D) image reconstruction.[3,4] VoNavix allows the abdominal wall musculature to be visualised along with the perforating vessels, as opposed to standard CTA illustrating the arteries on a background of the adjacent bony skeleton. The novel software has not yet been used in the field of perforator flap planning in plastic surgery. We recently started using it as part of our preoperative work-up for our free DIEP and MS-2 breast reconstruction patients.

We have now performed over 60 such cases using CTA. Of these, 10 cases used the VoNavix software. This paper presents our initial experience with this technique using three case reports as illustrative examples. We discuss the apparent benefits of this new tool, including the learning-curve, the effect on our operative planning and the actual surgery.

Computerised tomography angiography (CTA)

CTA is an objective, reproducible non-invasive radiological tool that is ideally suited to perforator mapping and free perforator flap tissue transfer planning. It reduces the potential for inter-observer error that is encountered with other techniques such as Doppler ultrasonography. CTA is able to quantify the intramuscular course of the perforators, their calibre and allow visualisation of the exact location of the vessels as they exit the muscle. In our unit, the multislice 32 slice CT scanner is used. Iodonated contrast (100 ml) is administered at 4 ml/s to produce a CTA from the level of the diaphragm to the femoral heads. Smart prep predicts the delay and images are acquired at 0.625 mm to allow full reconstruction.

Practical application of the software

VoNavix was originally developed for use in stereotactic surgery for joint replacement and facial bone surgery. But we have now applied it to the field of 3D perforator vessel mapping. The software is able to import DICOM-compatible (Digital Imaging and Communications in Medicine-compatible) data from a variety of imaging modalities. For the purpose of a DIEP flap, a standard CTA with fine cuts (0.625 mm) is acquired of the donor site and pedicle. Areas of anatomical interest are selected using the process of segmentation. Components of the donor site can be segmented and highlighted in contrasting colours. This process is repeated for the pedicle, rectus muscle, perforators and skin. The resulting 3D image can be viewed at any desired angle and the muscle component of the segmentation peeled away to reveal the intramuscular course of the perforator. In addition to providing an image, the VoNavix software can be used with stereotactic navigational equipment to locate the desired perforator intraoperatively.

There is a short learning curve associated in familiarising oneself with the software. It then takes approximately 30 min to create the image. The image can be created prior to surgery, but it can also easily be done on the morning of surgery whilst the patient is being prepared for theatre. The images are then loaded on to the intra-hospital imaging system, allowing full visualisation of the perforator from any angle on the computer in the operating theatre.

We present three cases that demonstrate the use of this technology in the operative setting.

Case 1

Case 1 is a 56-year-old patient who had previously undergone a right mastectomy for multi-focal ductal carcinoma in-situ (DCIS) and a small focus of Grade I adenocarcinoma. In addition, she previously had a Caesarean section through a lower midline scar and a nephrectomy on the left side. Preoperative investigations included a 'triple assessment' of CTA and VoNavix, hand-held Doppler ultrasound perforator mapping and also the use of the VoNavix stereotactic navigation device (Figure 1). Good correlation was found between the three modalities, as illustrated in Figures 2 and 3.

Furthermore, in surgery the vessels encountered matched up exactly with those on the 3D reconstruction (Figure 4). Due to the configuration of the vessels an MS-2 TRAM was performed. The flap ischaemia time was 77 min, the venous anastomosis was performed with a 3 mm venous coupler (Synovis Micro Companies Alliance Inc., USA) and the artery was hand-sutured using 9/0 S&T (Neuhausen, Switzerland). The patient recovered well and no flap complications arose.

Case 2

Case 2 is a 50-year-old woman who requested a delayed right free abdominal flap breast reconstruction following a mastectomy 3 years previously. Preoperatively her abdominal vascular anatomy was investigated using CTA and VoNavix software in addition to a colour Doppler duplex ultrasound (Figures 5 and 6). Intraoperatively two good medial row perforators were identified and used in the DIEP flap raised (Figure 7). The flap ischaemia time was 50 min, a 2.5 mm venous coupler was used for the venous

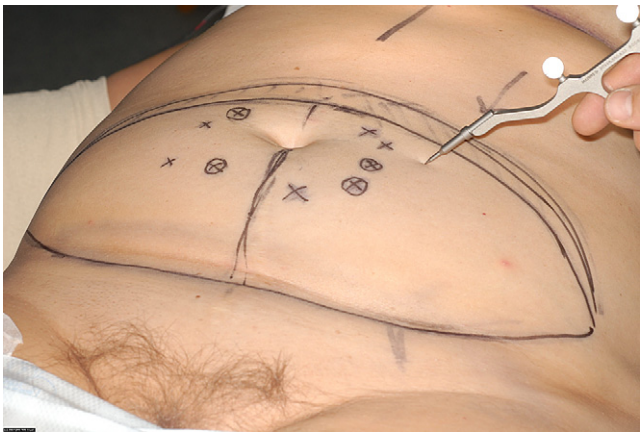

Figure 1 Preoperative planning with triple assessment: hand-held ultrasound Doppler and VoNavix navigation system in Case 1. The black crosses have been marked after mapping with the hand-held Doppler ultrasound and the navigation probe or 'wand' is shown in the photograph. Those with a cross and a circle denote a particularly strong signal from the hand-held ultrasound Doppler.

anastomosis and the arterial anastomosis was sutured using 9/0 S&T. No postoperative flap complications ensued.

Case 3

Case 3 is a 51-year-old woman who had an immediate breast reconstruction on the left side using an expander implant 5 years previously. Due to problems with a Baker grade 3 capsular contracture, she elected to undergo an autologous breast reconstruction using a free abdominal flap. CTA and 3D reconstruction using VoNavix software was undertaken as part of the preoperative work-up. The pictures obtained (Figure 8) showed a good lateral row perforator on the right (contralateral) side. Furthermore, on close analysis the perforator was shown to have a short intramuscular course (Figure 9a and b). It also demonstrated a significant superficial epigastric system (Figure 10).

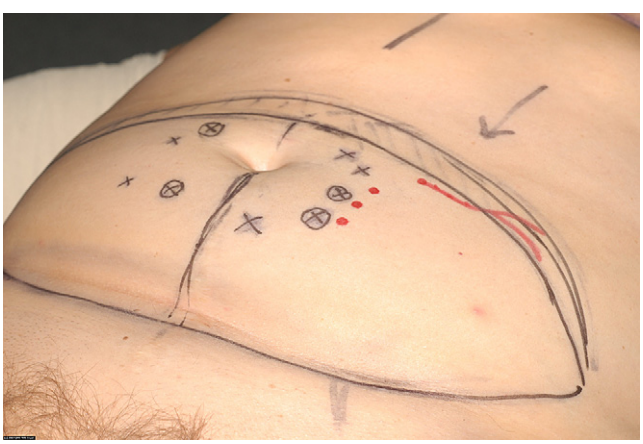

Figure 2 Good correlation shown between hand-held Doppler ultrasound (circled black crosses) and VoNavix mapping (red spots) of dominant perforator in Case 1.

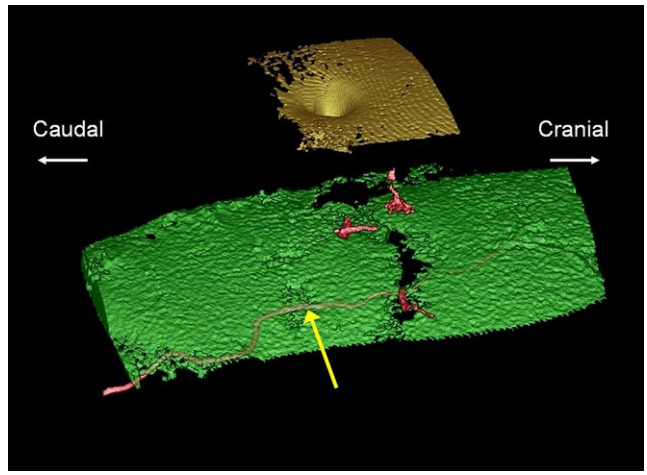

Figure 3 Preoperative CTA and 3D reconstruction using VoNavix software of the dominant perforator in Case 1 (yellow arrow).

Intraoperatively the superficial system did not appear quite as significant as that suggested by the VoNavix. However, a large lateral row perforator was found at the location expected. An MS-2 flap was raised on the lateral row perforator. The remainder of the breast reconstruction was performed without any complications, using a 2.5 mm venous coupler for the vein (as is our routine practice) and 9/0 S&T for the artery; the flap ischaemia time was 68 min. The patient went on to make an uneventful recovery.

Discussion

CTA with 3D reconstruction is amongst the latest imaging technology currently available.[5] It is therefore desirable for it to be used at the leading edge of plastic surgery reconstruction. The evolution of autologous breast reconstruction using free abdominal tissue has taken us from the free TRAM flap to the muscle-sparing TRAM and most recently to

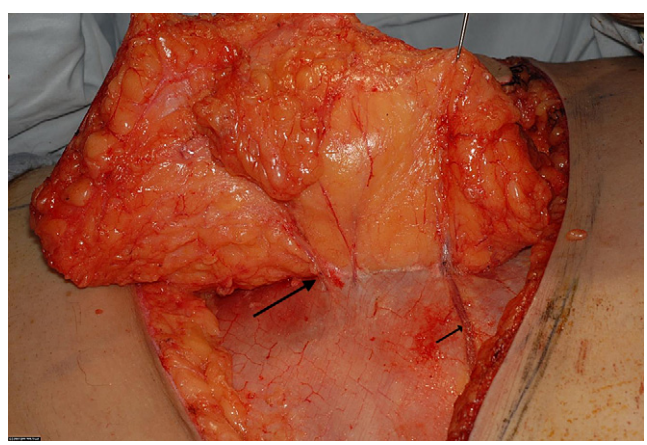

Figure 4 Intraoperative dissection of the dominant perforator in Case 1 (indicated by the large arrow). Note the transverse course of an additional vessel (indicated by the small arrow) that can be seen in Figure 2 as the transverse red line at the top of the flap.

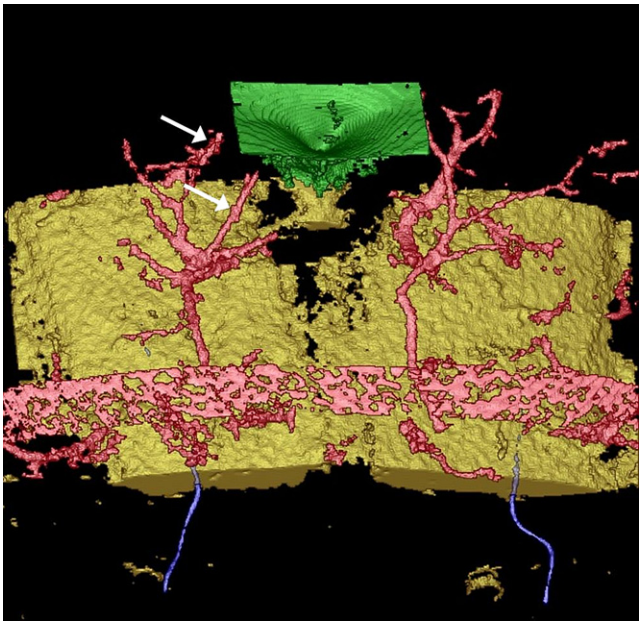

Figure 5 Preoperative demonstration of two good medial row perforators on the right using CTA and VoNavix in Case 2 (indicated by the two white arrows).

the DIEP flap. Up until recently it has been our practice to perform muscle-sparing TRAM flaps (MS-2).[6] Due to the growing evidence of reduced donor-site morbidity, DIEP flaps have become the first choice for breast reconstruction. However, we feel that there are certain patients in whom a DIEP flap confers no added benefit due to the perforator vessels taking a long intramuscular course. It is therefore desirable to be able to predict which patients fall into this category.

Imaging and preoperative planning of abdominal flaps are advantageous in terms of speed, safety and surgeon comfort in the operating room. The VoNavix software has enabled us to accurately delineate the course of the perforators across the whole abdomen in individual patients, which has then allowed us to effectively run through raising the flap preoperatively. This has permitted us to make firm preoperative decisions as to which side the flap will be pedicled on, and also whether we should raise a muscle-sparing TRAM flap (MS-2) in patients with small perforators, or those in which there is a long intramuscular course. We prefer to use muscle-sparing TRAM flaps in cases with small perforators, primarily to aid venous drainage from the flap. It also provides important information in those patients who have undergone previous abdominal surgical procedures; especially in cases where a bilateral breast reconstruction is required, so both sides of the abdomen are needed.

Figure 6 Preoperative localisation of the dominant perforators in Case 2 with Doppler ultrasound (circled black crosses). Note how the positions of these dominant perforators compare with those in Figure 5. The other dots represent points with weaker Doppler signals.

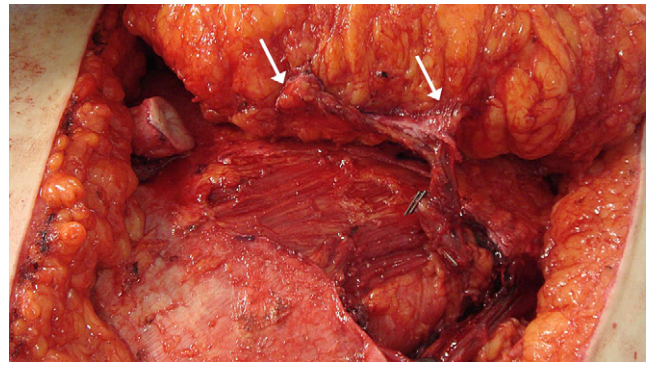

Figure 7 Intraoperative dissection of the right medial perforators (indicated by the white arrows) as previously demonstrated preoperatively by 3D reconstruction in Case 2. The umbilicus/superior edge of the dissection is on the left side of the picture. Note the moderate rectus divarication.

It has been difficult to quantify the perceived advantages of this sort of preoperative planning for this preliminary study, mainly due to high numbers of different surgeons (including trainees) raising these flaps in our unit. However, it has been universally acknowledged by surgeons at all levels to be an invaluable asset (including the two senior authors who have been performing this surgery for approximately 20 years each). This ranges from the training perspective, enabling the junior surgeon to be 'walked through' the operation beforehand, to the senior surgeon

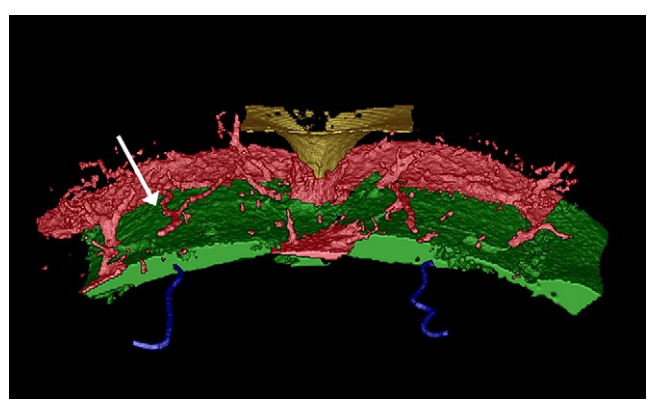

Figure 8 Transverse view of the preoperative 3D reconstruction showing a good lateral row perforator (indicated by the white arrow), coloured blue below the rectus muscle (green) and pink above the rectus on the right side in Case 3. This dominant lateral row perforator appears to have a short intramuscular course.

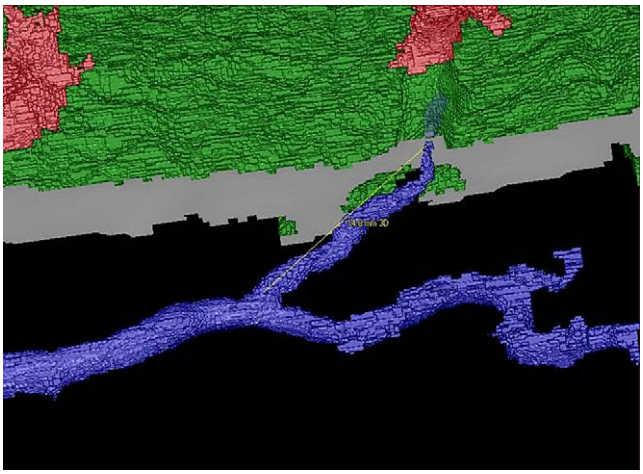

Figure 9 Sagittal view of the different perspective and magnification of the preoperative 3D reconstruction confirming the short intramuscular course of the perforator in Case 3.

deciding on which specific type of abdominal flap to choose, and which side to base the pedicle on.

Some care in interpreting images of this sort should be exercised as the vasculature of the integument is a dynamic physiological system.[7] Thus images obtained at one sitting, i.e. during CT scanning, may not truly represent what is seen during surgery, or indeed be representative for that patient. For example, perforators may not be visualised on CTA if the scan is taken with the patient in a particular position or phase of respiration. Another potential disadvantage is the occasional misleading artefact, such as the suggestion of a good superficial system as mentioned in Case 3. Notwithstanding this, at present this is the most advanced imaging and preoperative planning that exists. As with any novel equipment, there is a learning curve to using the software. Once familiarised with the construction of the images however, due to their appearance, they are easily interpreted by the surgeon.

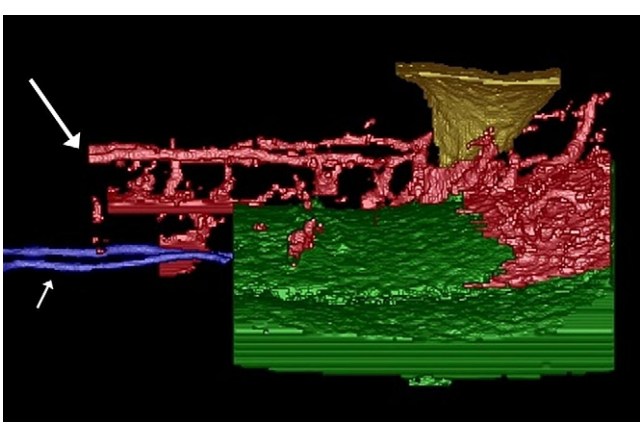

Figure 10 Preoperative 3D reconstruction showing the artefactual large calibre superficial system compared to the deep system in Case 3. The large arrow indicates the superficial system, while the small arrow shows the deep system. This problem is reviewed in the discussion section of the paper.

When using the navigation software, it is necessary to register the CT with the patient. This is done by matching fixed anatomical points (registration points) on the scan with fixed anatomical points on the patient. These points have to be fixed so that there is no movement of the points between CT scanning and operation. They also have to be readily identifiable with a degree of accuracy. The points we have used are the umbilicus, the upper end of the vulva and skin creases or the anterior superior iliac spine laterally. Movement of these points and difficulty of identification is the limitation of accuracy of the navigation system. Nevertheless, even with this limitation, it is possible to get accuracy to within 5 mm of the area identified by CT. This level of accuracy is a calculated level of accuracy within Voxim software. It is based on the discrepancy between the 3D relationship of the registration points recorded from the patient and the same measurements taken from the CT scan. This compares to levels of accuracy of under 0.5 mm in the bony facial skeleton where fixed anatomical points are easier to register. We then often use the hand-held Doppler probe to complete a 'triple assessment' of the perforators preoperatively to produce the most accurate picture possible (see Figures 1 and 2). Once the patient is on the operating table, a hand held 'wand' (see Figure 1) is used to match points on the patient to the corresponding points on the scan. Following this, wherever the 'wand' is placed on/in the patient, the corresponding area on the scan is highlighted. Further studies are underway to further improve the accuracy of this system.

Other groups have found different methods of preoperative imaging helpful, but these usually rely on colour Duplex or routine CTA or magnetic resonance angiography (MRA). In 1998, Blondeel et al.[8] scanned the abdomens of 50 consecutive patients using colour Duplex prior to abdominal flap breast reconstruction. They encountered a true positive rate of 96.2% and a positive predictive value of 100%. The mapped perforators were marked on the abdomen by the scanning radiologist. Although shown to be highly accurate in siting the perforators, the disadvantage of colour Duplex scanning is the inability to produce a 3D, easily-interpretable picture that can be referred to pre- and intraoperatively. It requires a highly-skilled operator to perform the scan, can be difficult in patients with a high BMI, takes a significant amount of time (at least 20 min) and gives no indication as to the perforator's intramuscular course. CTA images are acquired in a single breath-hold and technically achievable in almost all patients independent of body habitus. They have a better spatial resolution and are not prone to movement artefacts as is the case with MRA sequences.[9] The main disadvantage with CTA is the fact that the examination does involve both ionising radiation as well as the injection of iodinated contrast medium. Furthermore, veins may be seen, but not consistently, and they cannot be differentiated from arteries on the basis of the CTA appearances alone. Other techniques have been evaluated but are not yet refined enough to be used in routine preoperative work-up, e.g. scanning laser Doppler.[10]

In conclusion, the advantage of the VoNavix software, when used in conjunction with an image assessment such as CTA, is that it provides accurate visual detail of the site of the best perforator(s) and its course through the muscle.

This enables optimal preoperative preparation for both surgeon and operating team. It also allows prediction of potential technical difficulties, as well as giving the surgeon additional familiarity with the individual case preoperatively. Perhaps its most powerful use so far is to allow a preoperative decision to be made regarding the inclusion of muscle in the flap. Furthermore, it aids the teaching of more junior trainees in the art of assessing patients and raising DIEP flaps for breast reconstruction. Whilst we have applied this software to DIEP/TRAM breast reconstruction, there is no reason why it could not be used in the preoperative planning of perforator flaps elsewhere. *Disclosure*: None of the authors have any financial interest in the equipment used in this study.

Acknowledgements

We would like to thank the League of Friends, Queen Victoria Hospital, for their donation of VoNavix.

References

1. Allen RJ, Treece P. Deep inferior epigastric perforator flap for breast reconstruction. *Ann Plast Surg* 1994;**32**:32—8.
2. Vandevoort M, Vranckx JJ, Fabre G. Perforator topography of the deep inferior epigastric perforator flap in 100 cases of breast reconstruction. *Plast Reconstr Surg* 2002;**109**:1912—8.
3. Coenen VA, Dammert S, Reinges MH, et al. Image-guided microneurosurgical management of small cerebral arteriovenous malformations: the value of navigated computed tomographic angiography. *Neuroradiology* 2005;**47**:66—72.
4. Leong JL, Batra PS, Citardi MJ. Three-dimensional computed tomography angiography of the internal carotid artery for preoperative evaluation of sinonasal lesions and intraoperative surgical navigation. *Laryngoscope* 2005;**115**:1618—23.
5. Masia J, Clavero JA, Larranaga JR, et al. Multidetector-row computed tomography in the planning of abdominal perforator flaps. *J Plast Reconstr Aesthet Surg* 2006;**59**:594—9.
6. Nahabedian MY, Dooley W, Singh N, et al. Contour abnormalities of the abdomen after breast reconstruction with abdominal flaps: the role of muscle preservation. *Plast Reconstr Surg* 2002;**109**:91—101.
7. Taylor GI, Palmer JH. The vascular territories (angiosomes) of the body: experimental study and clinical applications. *Br J Plast Surg* 1987;**40**:113—41.
8. Blondeel PN, Beyens G, Verhaeghe R, et al. Doppler flowmetry in the planning of perforator flaps. *Br J Plast Surg* 1998;**51**: 202—9.
9. Osborn A. Intracranial vascular malformations. In: Osborn A, editor. *Diagnostic neuroradiology*. St. Louis: Mosby; 1994. p. 284—329.
10. Komuro Y, Iwata H, Inoue M, et al. Versatility of scanning laser Doppler imaging to detect cutaneous perforators. *Ann Plast Surg* 2002;**48**:613—6.